

# Laparoscopic colon and rectum resection with transanal specimen extraction

Rodriguez-García JI, Solar García L., Gonzalo González R., González Tamargo A., Llaneza Folgueras A., González González J.J  
Department of Surgery Hospital Universitario Central de Asturias, Oviedo, Spain

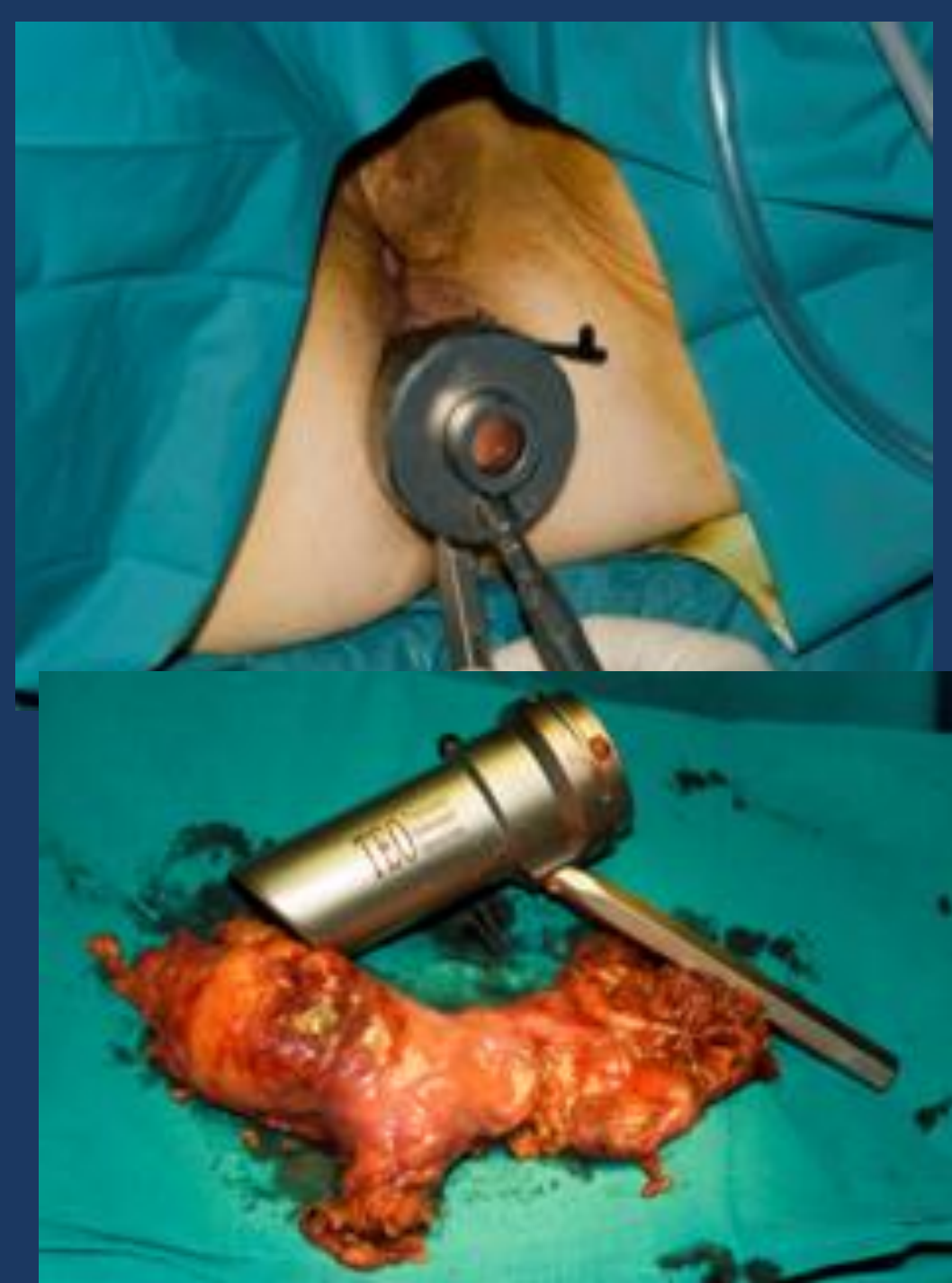


Figure 1

## Background:

Minimally invasive surgery for colon resection is nowadays the approach of choice for the majority of colorectal disease. However a small laparotomy is necessary to assist the procedure and as a consequence infection and other wound complications are not infrequent.

To overcome these problems in some selected patients a transanal specimen extraction was performed.

## Patients and Methods:

Between October 2009 to March 2011 twelve patients who underwent elective laparoscopic colon or rectum resection were selected for this technique. In all cases the lesion was without masses or with small size tumors in the left-sided colon or upper rectum. Preoperative and technical operative data and short term outcome were analyzed.

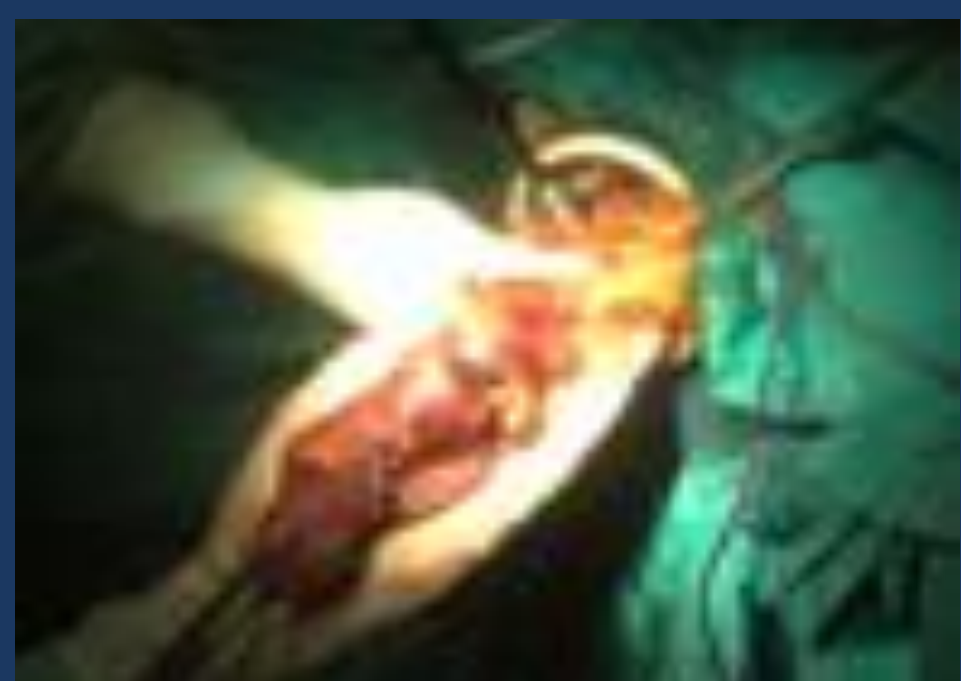
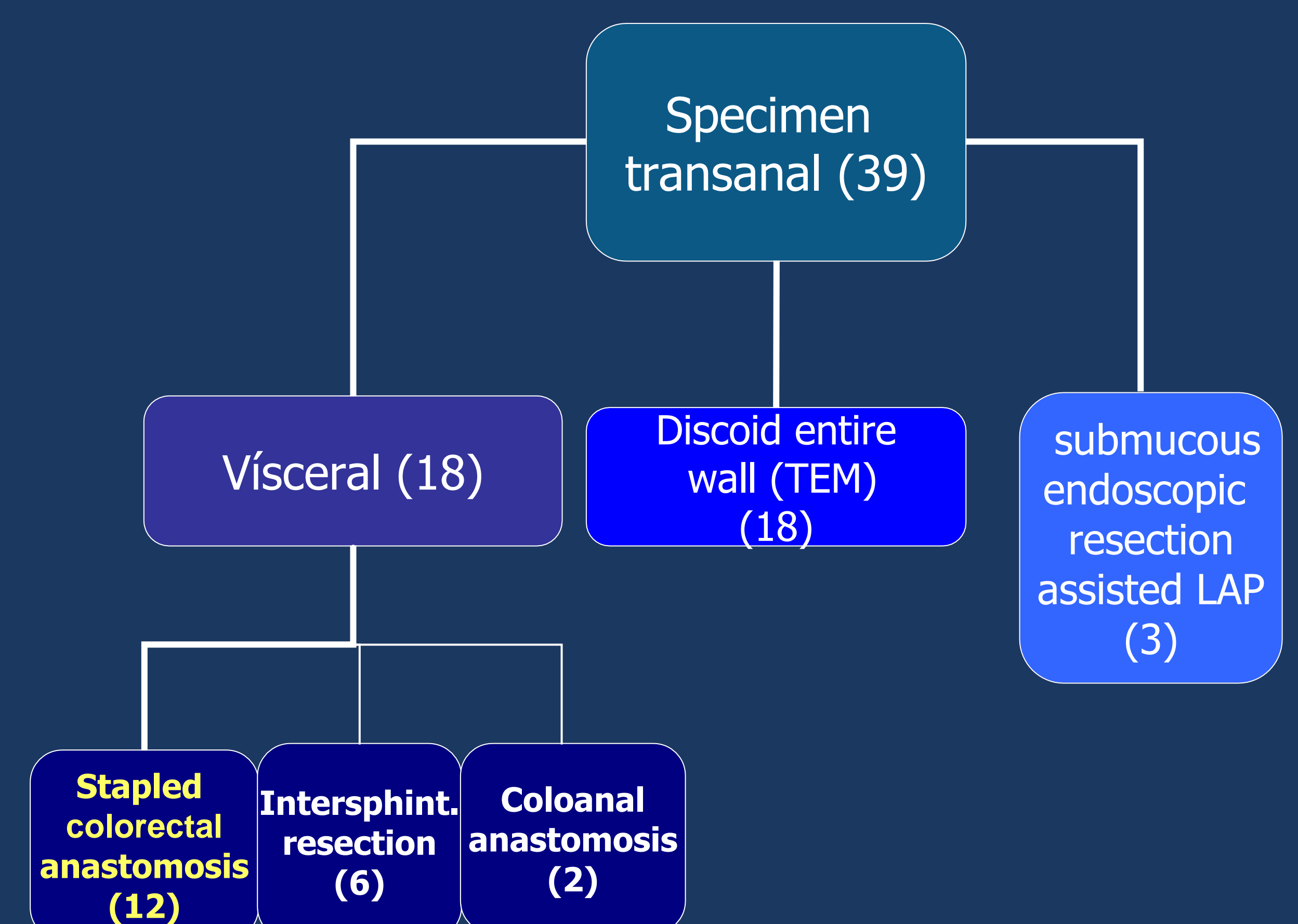


Figure 2



## Results

Median age was 66 years and 8 were women. Ten patients had a malignant tumor, one sigmoid diverticular disease and the last one dolicolon with colonic volvulus episodes. Median operative time was 165 minutes. The transanal specimen extraction was carried without complications and facilitated by a TEO device in 5 cases (Figure 1), directly with grasper in 4, with Alexis<sup>R</sup> (Applied Medical) in 2 (Figure 2) and with a plastic bag one (Figure 3). After a stapled colorectal anastomosis was performed.

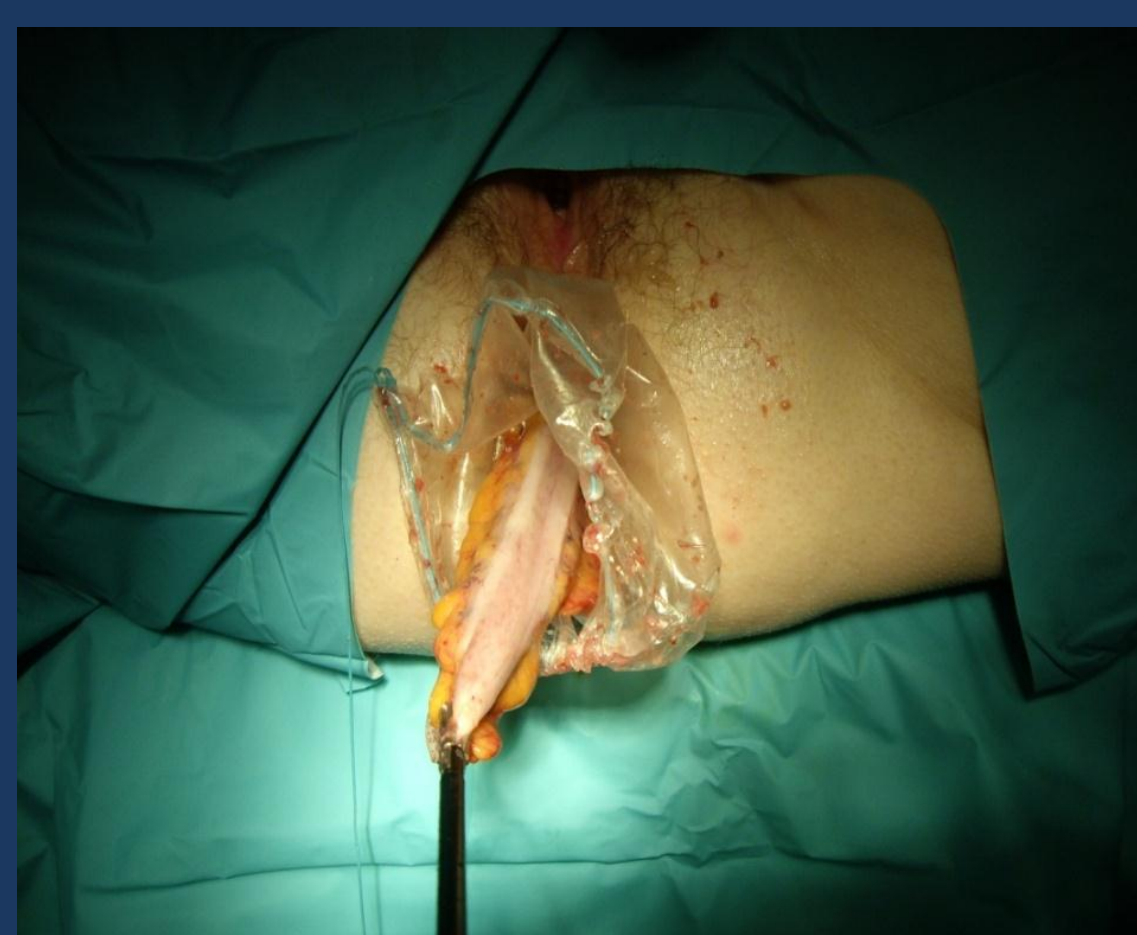


Figure 3

In one of the patients a prolonged adynamic ileus was observed. None of the patients required blood transfusion. In hospital or 30-day mortality was zero.

## Conclusions

Transanal specimen extraction after laparoscopic colorectal resection is feasible and without complications in selected cases.